

**FAQ 58**  
(September 18, 2007)

**58.1**

**Q: I read on the Bethshort.com website where you mentioned that George Hodel besides posing the body as the MINOTAUR also cut lacerations on the upper lip to imitate another Man Ray painting, THE LOVERS. I would like to challenge you on that. I'm familiar with the painting and no such markings exist.**

Actually, they do.

I am not a Man Ray expert and before beginning my investigation in 1999, was totally unfamiliar with his artwork, other than the eight photographs he took of my family in the 1940s.

As most readers are aware, in 2003 I presented my theory that SURREALISM could well be the key to understanding the Elizabeth Short crime scene. I posited that George Hodel had incorporated two Man Ray's artworks, THE LOVERS and THE MINOTAUR as part of his macabre homage to the artist, his close friend and guru.

In 2006, just prior to making a presentation at the Pompidou Centre in Paris, I made what I believe may well be an additional link specifically as relates to THE LOVERS painting. I discovered a separate Man Ray photograph, also made in the 1930s. Incredibly, in this work, Man Ray had actually combined the LOVERS LIPS with a woman's nude bisected body! And more! In this photograph I could see he had included something additional. In this version he had inserted five linear cuts on the lower lip.

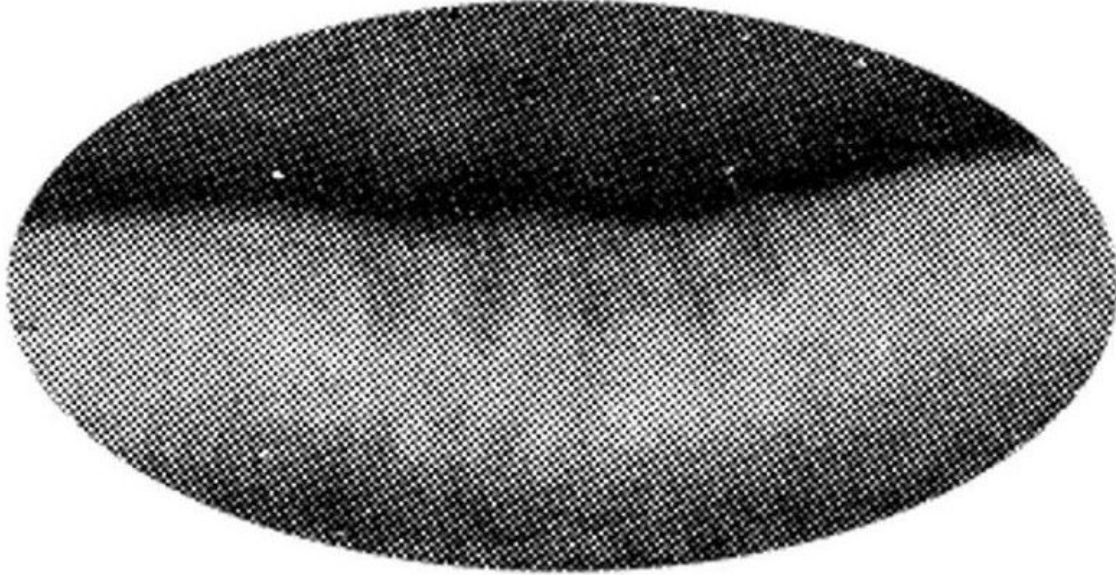
What were they? What did they represent? (I knew from Man Ray's biography that the LOVERS LIPS were those of Lee Miller, his ex-lover, who after their breakup would become his, "Object to be destroyed." As in most surreal works, Man Ray's meaning and reason for including these markings remains enigmatic, relegated to the world of dreams and the unconscious. You may see them as a bad case of "chapped lips". Another may view them as nothing more than wrinkles. Open to individual and subjective interpretation. However, what we do know is, they are not simply the slip of a paintbrush. They do have a meaning.

What I see are more crime scene signatures, reinforcing my belief that my father was mimicking Man Ray's artwork while at the same time; in the true fashion of a dedicated Dadaist, he was fiendishly mocking society. His masterpiece of the macabre.

Again, I believe George Hodel, with his perfect photographic memory was including more plagiaristic hints. More variations on a theme. How?

In his "Work" George Hodel would make the same five vertical incisions as seen in Man Ray's art, but instead of placing them in the center and drawing them southward, he would use his scalpel paintbrush and place them to the left of his canvass (the victim's face) and draw (cut) northward into the soft tissue.

One more piece of a very complex puzzle, but it fits, and we now have more than a dozen separate Surrealist links in place. This "new" link which until last year I had no knowledge existed is important as it shows Man Ray himself in the 1930s had actually combined the lips with a bisected woman.



Man Ray photograph as it originally appeared in 1930s

Finally, let me simply quote verbatim from the **SECRET DA FILES**, which DA Steve Cooley granted me access to in 2003, post- publication of BDA. The below is an exact and unaltered excerpt from the autopsy summary as reported by LAPD to the DA investigators.

### **SUMMARY OF THE ELIZABETH (BETH) SHORT MURDER INVESTIGATION**

Page-3 of 22

...

#### **Paragraph 3-**

**“An autopsy was performed on January 16, by Dr. Frederick D. Newbarr, Chief Autopsy Surgeon, in association with Dr. Victor Cefalu, Assisant Chief Autopsy Surgeon. Present were Ray Pinker of the Scientific Investigation Division and Sgt. Hansen of Homicide Division. <sup>1</sup>This report contained the following:**

...

#### **Paragraph 4- (bottom)**

**“There are five linear lacerations on the right upper lip which extend into the soft tissues for a distance of 1/2”. [Emphasis mine] The teeth are in a state of advanced decay. The two upper central incisors are loose and one lower incisor is loose.**

...

I am not going to post the crime scene photograph showing the five linear lacerations as they are disturbing to view and this DA/LAPD description is sufficient to establish they exist as herein documented by the coroner.

---

<sup>1</sup> As a separate observation, it is interesting to note that at least in this official LAPD document it appears the only two officers in attendance at the Elizabeth Short autopsy were: Detective Harry Hansen and criminalist, Ray Pinker. This would seemingly contradict undocumented references that claim Det. Finis Brown and others were there.